

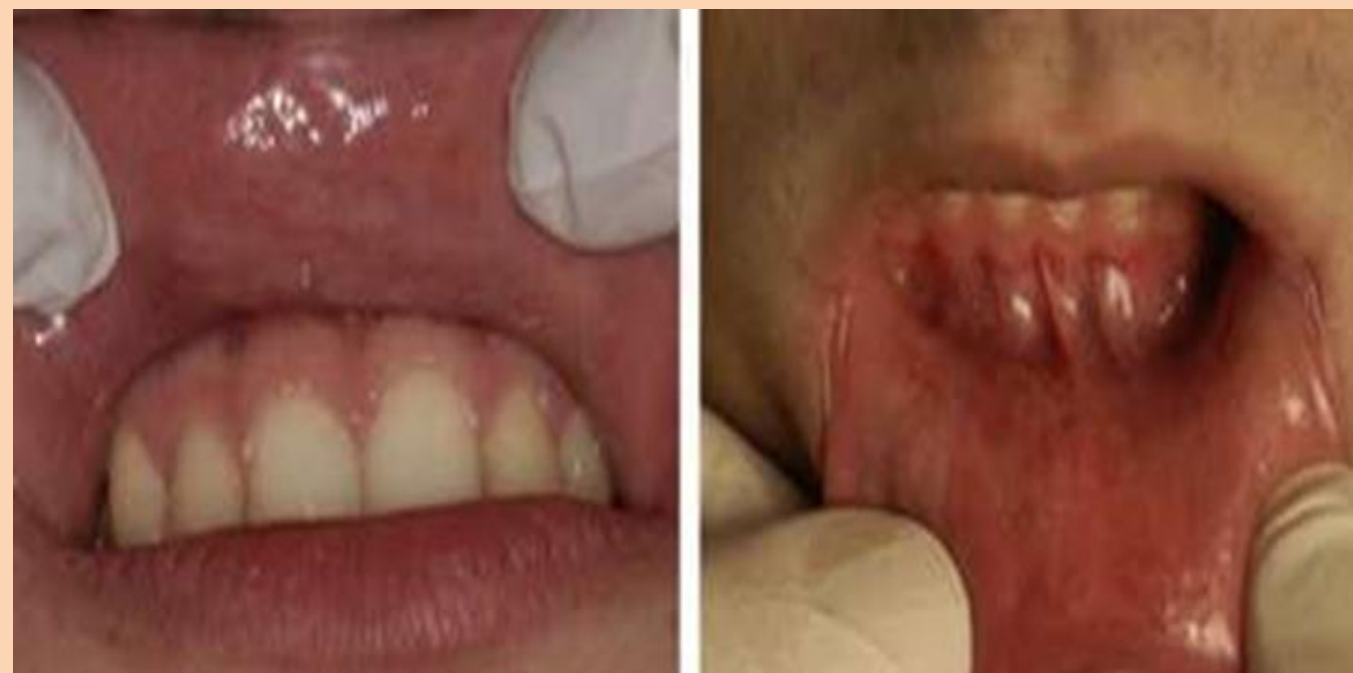

General Oral Examination

For FLW



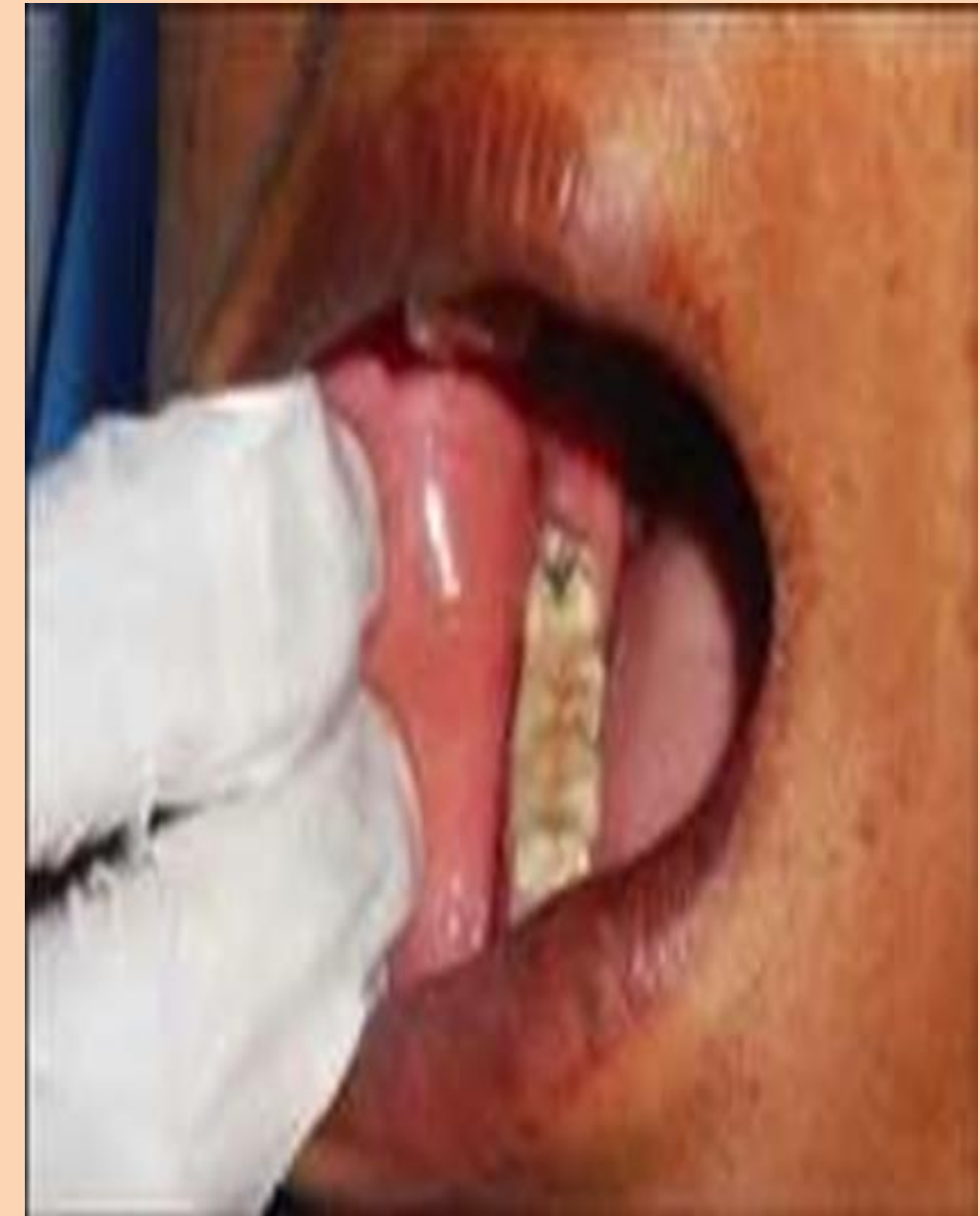1. LIPS



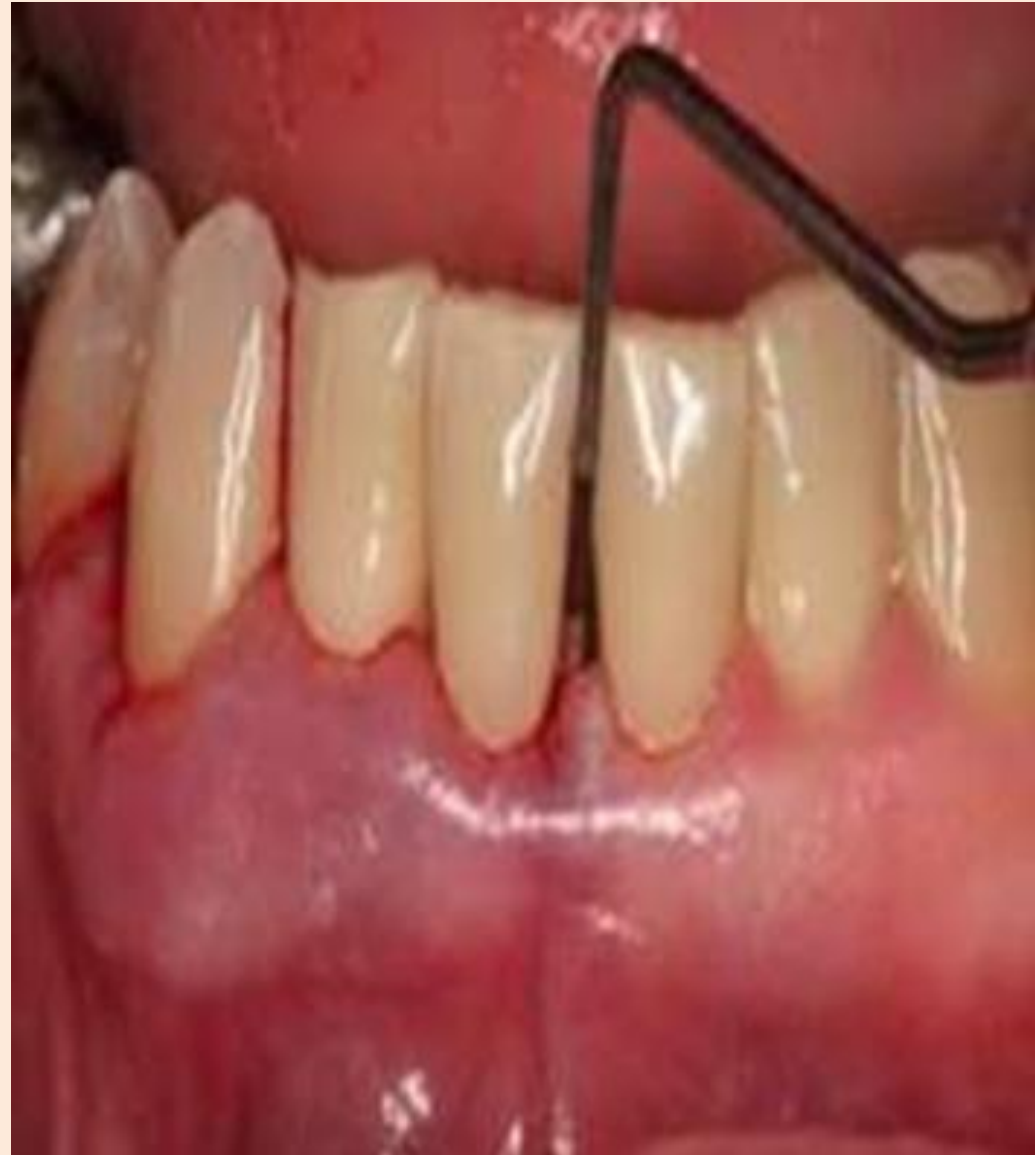- **Where** to look: Outer surface, inner lining and borders
- **What** to look: pigmentation, presence of ulcer, swelling, crust, dryness
- Normal: above mentioned should be absent, inner lining should appear wet and shiny

2. CHEEKS

- **Where** to look: the inside of the cheeks, using a mirrors/ index finger to push back the inner part of the cheek to one side.
- **What** to look: inspect for change in color, presence of any swelling and patches
- Normal: inner part should be smooth, moist, shiny and pink in color



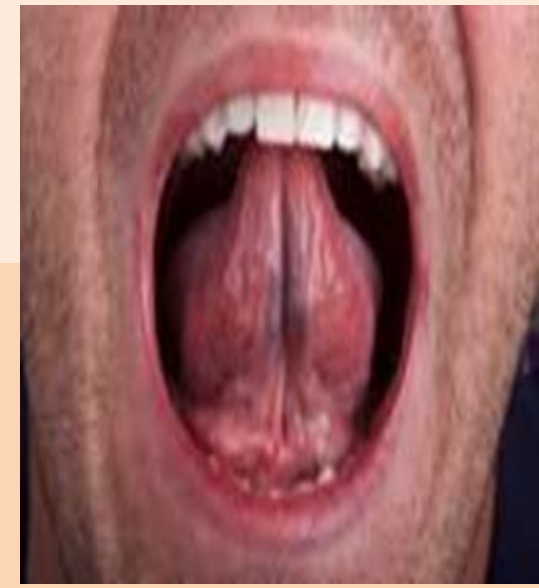3. GUMS



- **Where** to look: Inspect the gums for color, consistency, contour and size
- **What** to look: Examine gums for presence of any bleeding
- Normal: Healthy gingiva is pink, and regular



4. FLOOR OF MOUTH

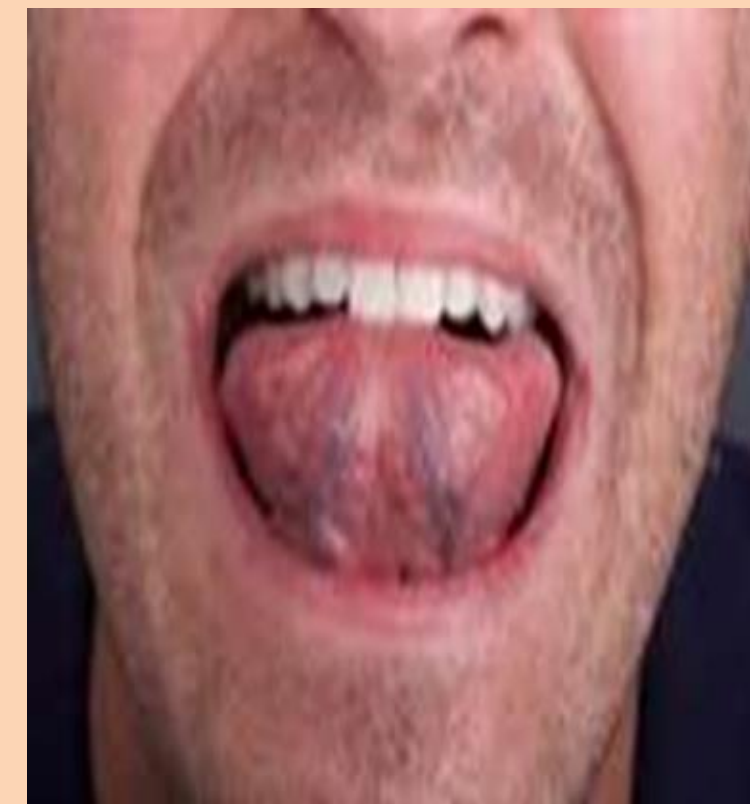

Examine by asking the patient to touch the roof of the mouth with tip of his tongue.

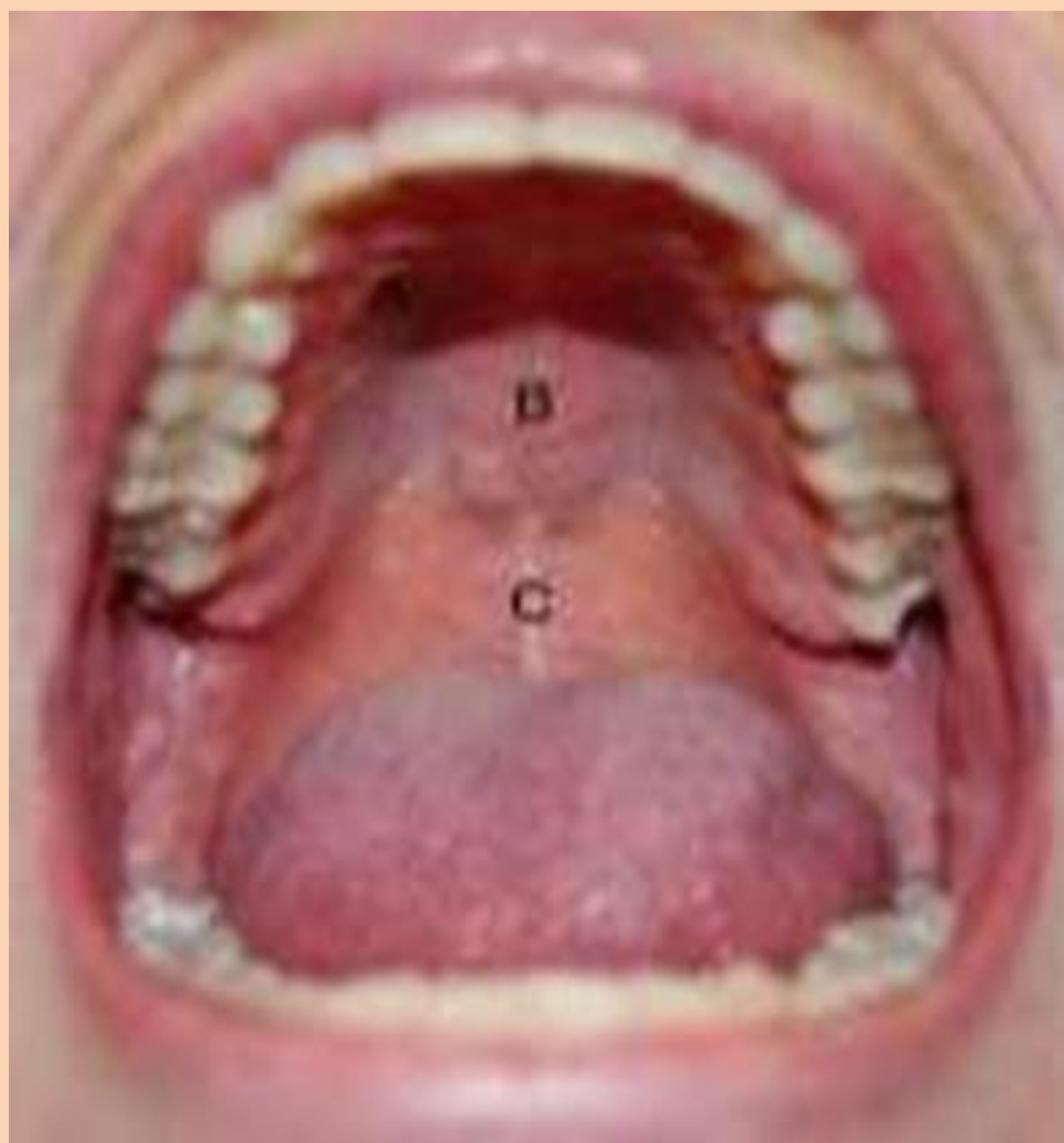- **Where** to look - in floor of the mouth.
- **What** to look for: Check for pooling of saliva in the floor of the mouth
- Normal - no saliva collection in the floor of the mouth

5. TONGUE

- **Where to look**
 - Examine **top** first by asking the patient to protrude the tongue forward, keeping the mouth open
 - To inspect the **lower** surface, patient is instructed to touch the roof of the palate with tip of his tongue
 - Check the **sides** of the tongue, movements of tongue and the floor of the mouth
- **What to look:** the appearance of ulcers, masses, red areas, or white areas can be early signs of cancer



6. HARD & SOFT PALATE



- **Hard palate** (bony part)- it is pink, firm and show corrugated pattern in anterior portion, check for change in color, swelling, ulcer, and cleft
- **Soft palate** (behind the hard palate)- reddish pink in colour, examine it for ulcer, swelling

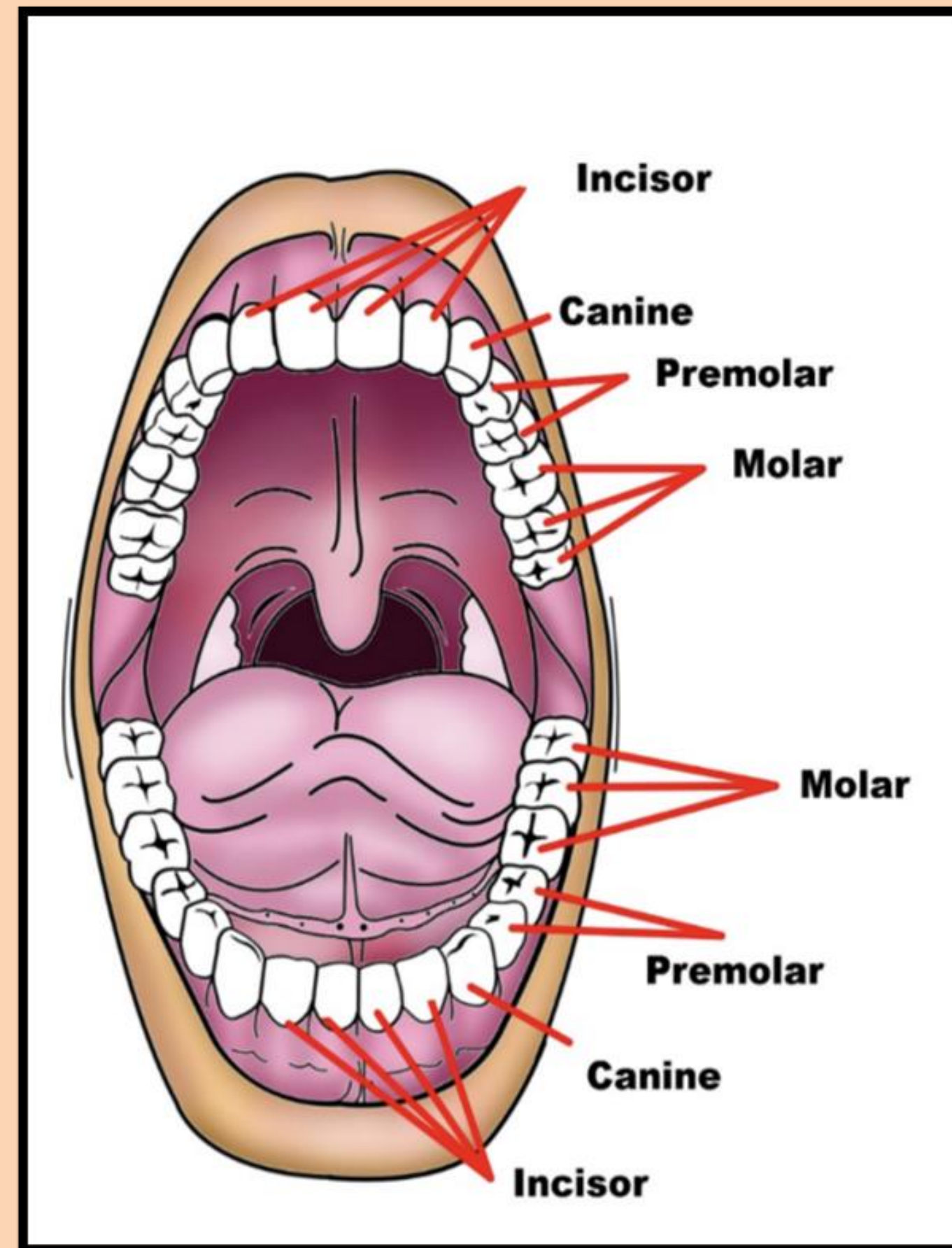
7. TEETH

Humans have 2 sets of teeth:

- Temporary Teeth- milk/ baby/ primary
- Permanent Teeth- adult

A total of 32 permanent teeth are there-

- 8 incisors,
- 4 canines,
- 8 premolars and
- 12 molars in both upper and lower arches.



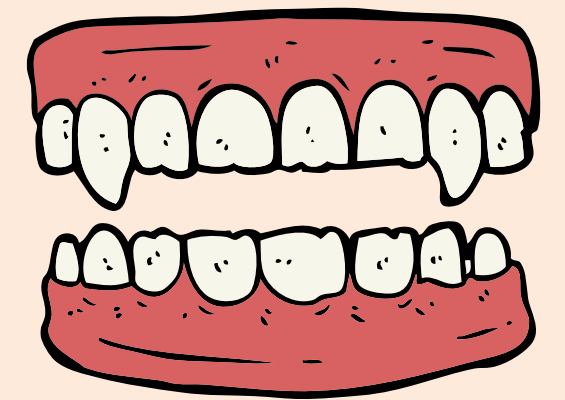Different types:

1. Incisors: They are front teeth, four in the upper arch and four in the lower arch. They are shaped to bite and cut food into small pieces.

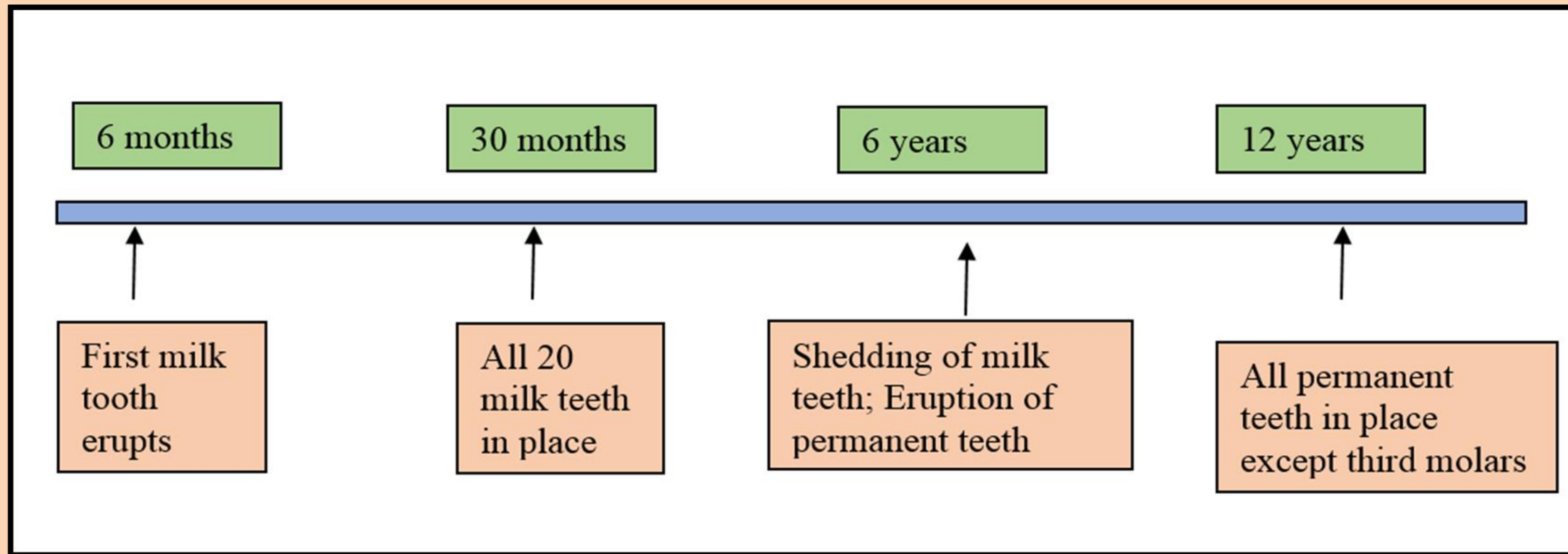
2. Canines: They are conical teeth at the corner of the mouth. Their function is to tear or shred food.

3. Premolars: These are two on each side of both the jaws just behind the canine. The function of these teeth is to hold and crush food. Premolars are present only in adults.

4. Molars: They are three in number on each side of the jaws and have bigger chewing surface for cutting food into smaller parts.



ERUPTION OF TEETH TIMELINE





सत्यमेव जयते



Thank You

