



General Oral Examination

For CHO/SN



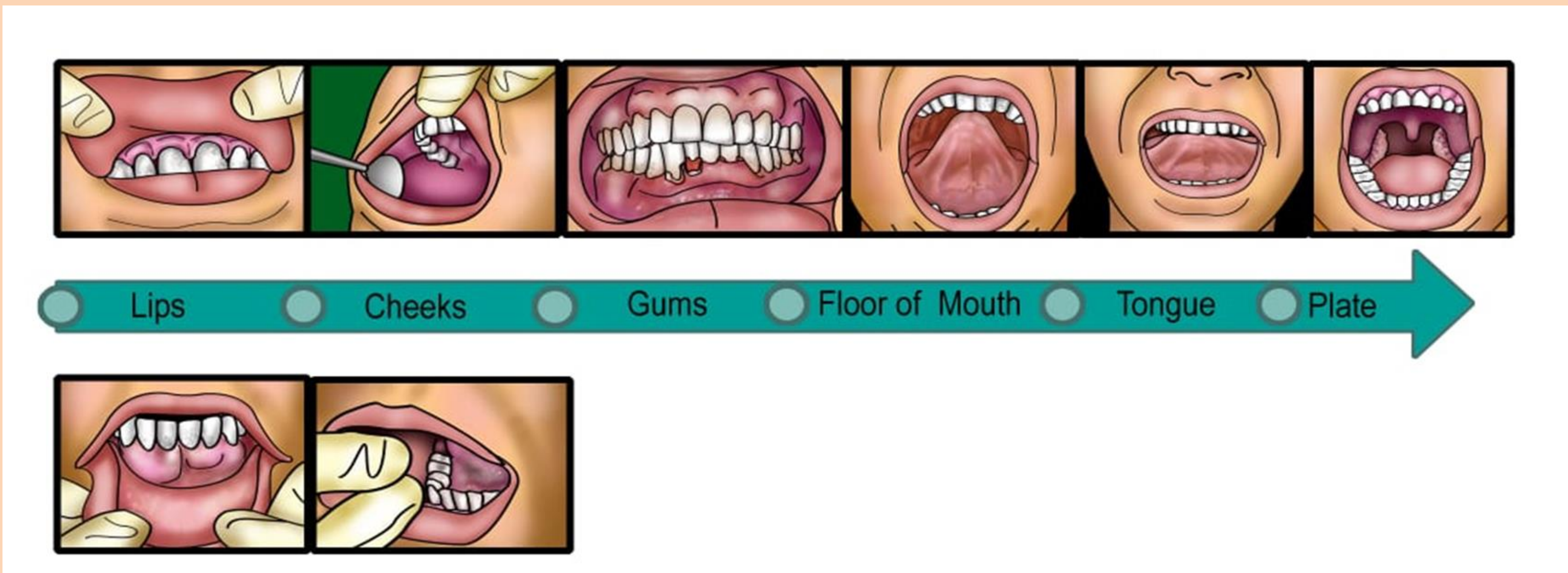


GENERAL EXAMINATION

- History taking- find out the nature of the problem and oral hygiene habits
 - Details of the current problem, any past dental or oral health problems
 - Details about oral hygiene care and current symptoms
- Examination of the oral cavity

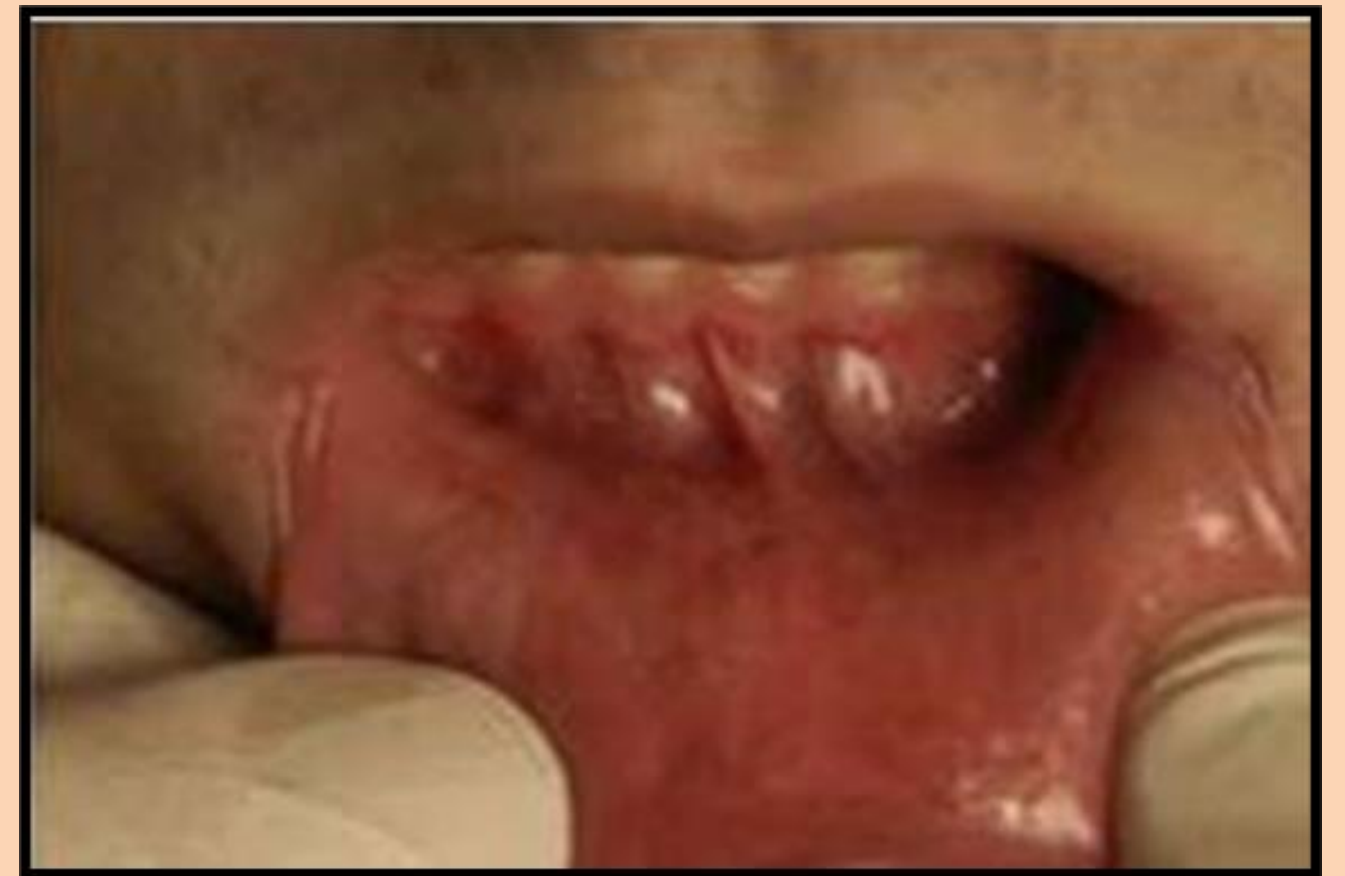
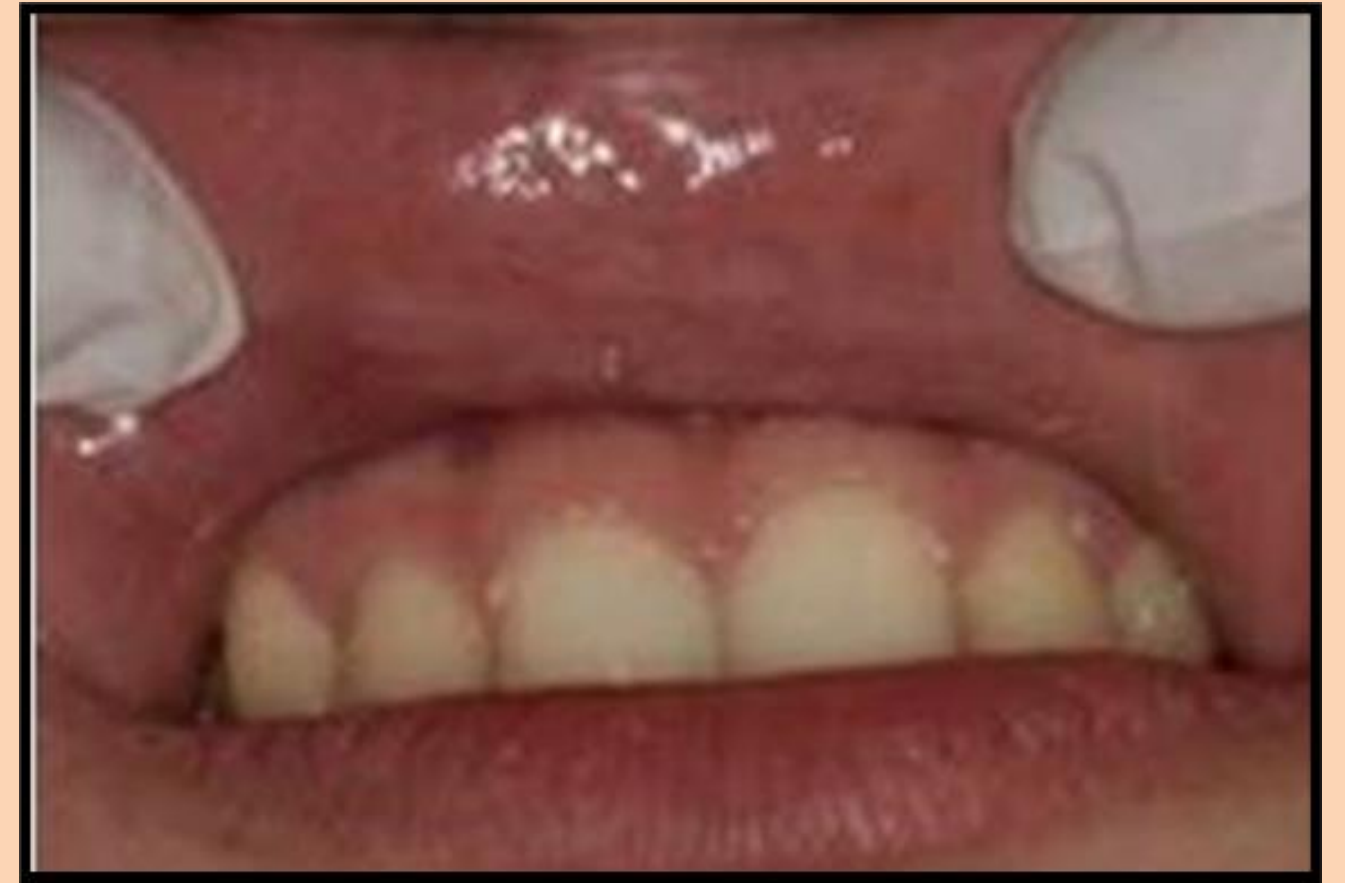
STEPS IN SYSTEMATIC ORAL EXAMINATION



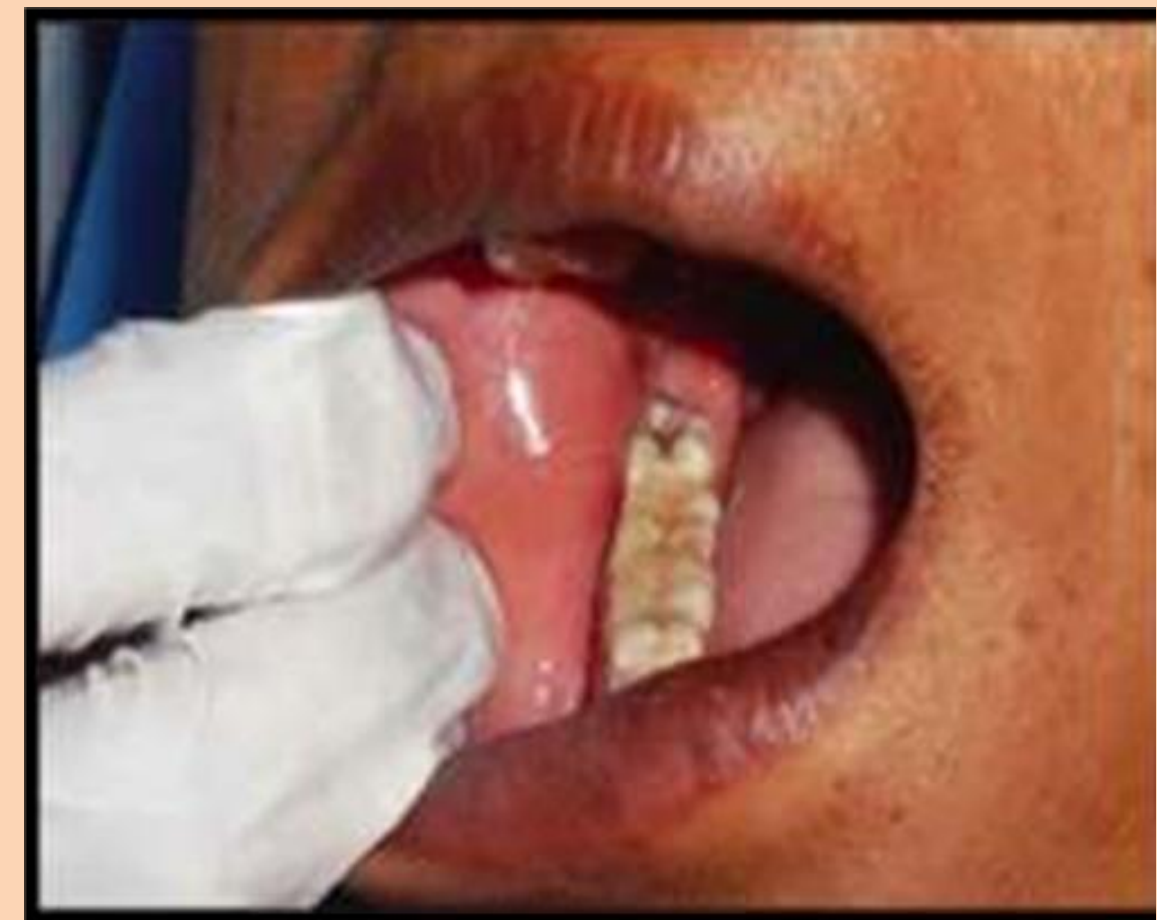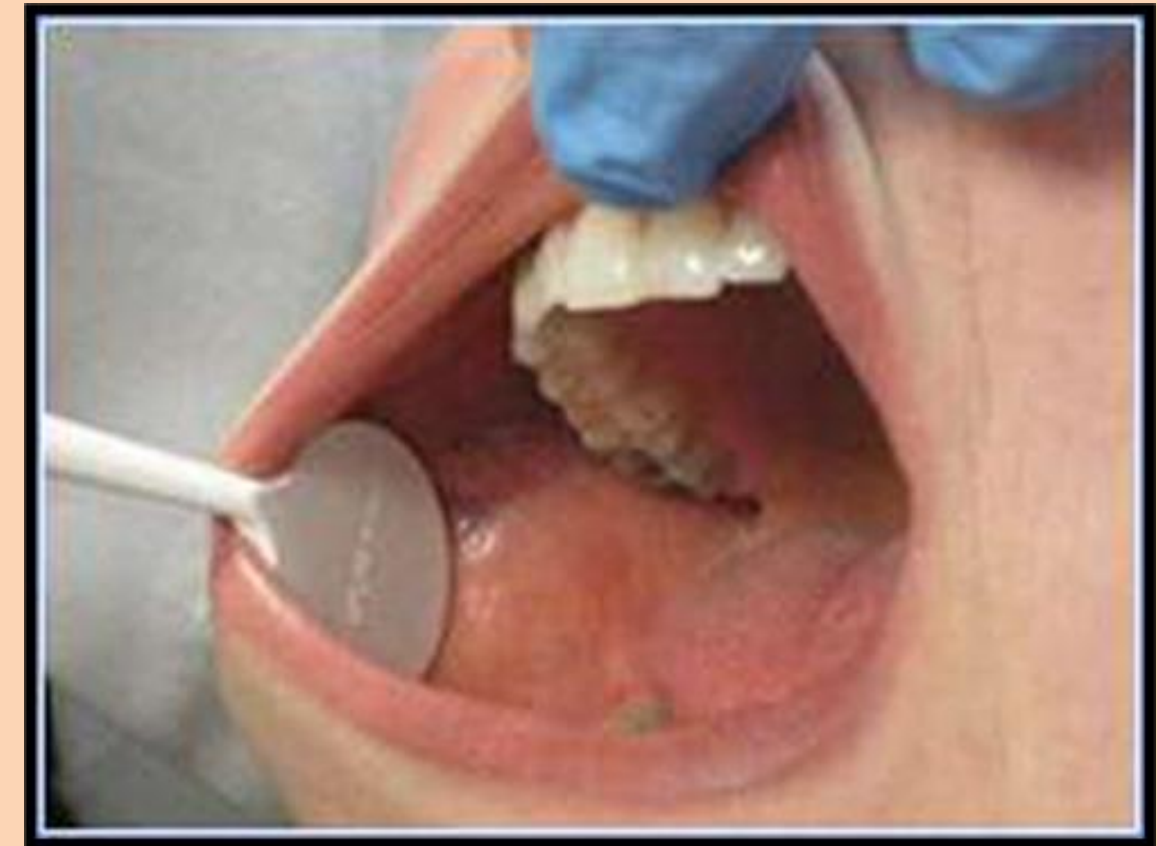1. LIPS

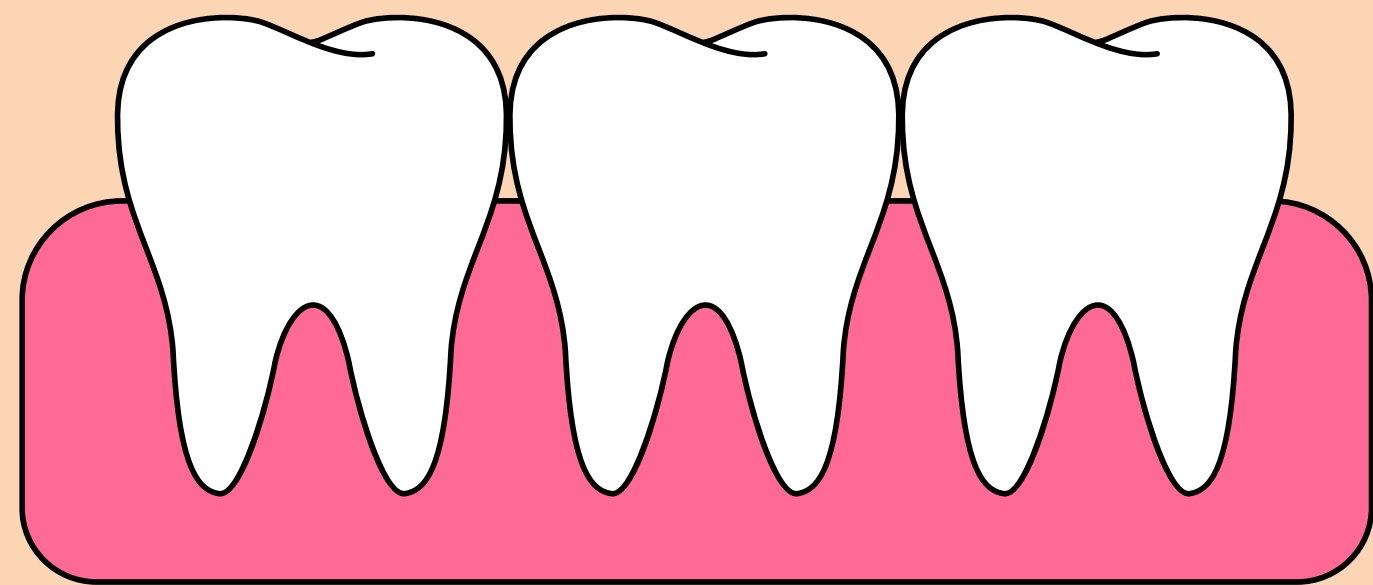
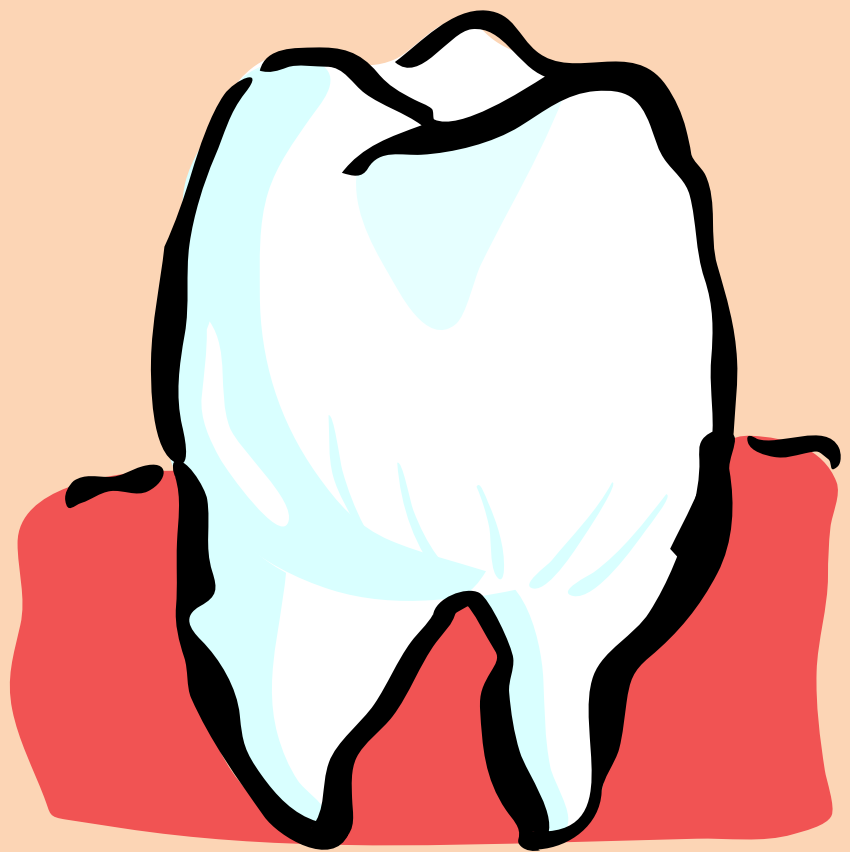- **Where to look:** Outer surface, inner lining, and borders
- **What to look:** Pigmentation, presence of an ulcer, swelling, crust, dryness
- **Normal:** Above mentioned should be absent, the inner lining should appear wet and shiny.



2. CHEEKS

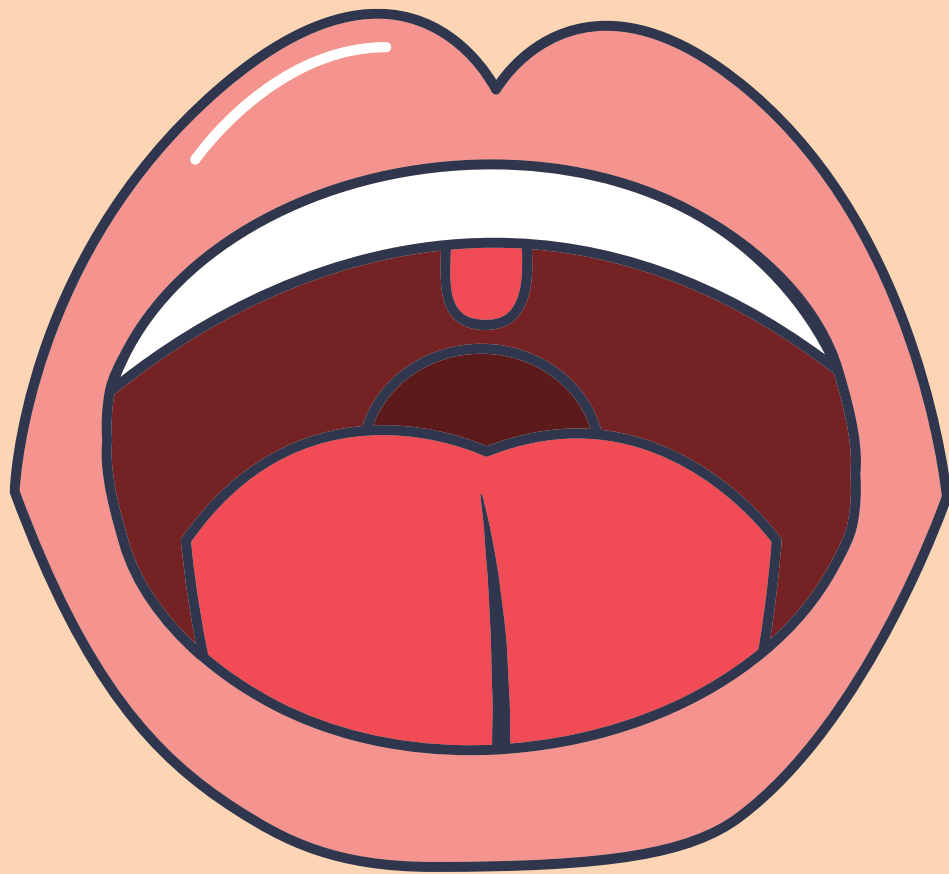
- **Where to look:** the inside of the cheeks, using a mirrors/ index finger to push back the inner part of the cheek to one side.
- **What to look:** inspect for change in color, presence of any swelling and patches
- **Normal:** inner part should be smooth, moist, shiny and pink in color





3. GUMS


- **Where to look:** Inspect the gums for color, consistency, contour, and size
- **What to look:** Examine gums for the presence of any bleeding
- **Normal:** Healthy gingiva is pink and regular



4. FLOOR OF MOUTH

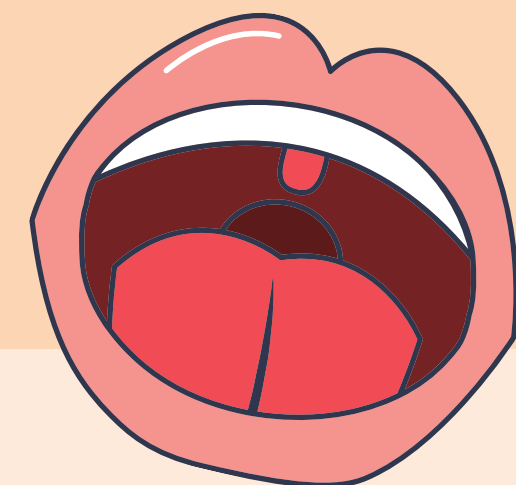
Examine by asking the patient to touch the roof of the mouth with the tip of his tongue

- **Where to look:** on floor of the mouth
- **What to look for:** Check for pooling of saliva on the floor of the mouth
- **Normal:** no saliva collection on the floor of the mouth



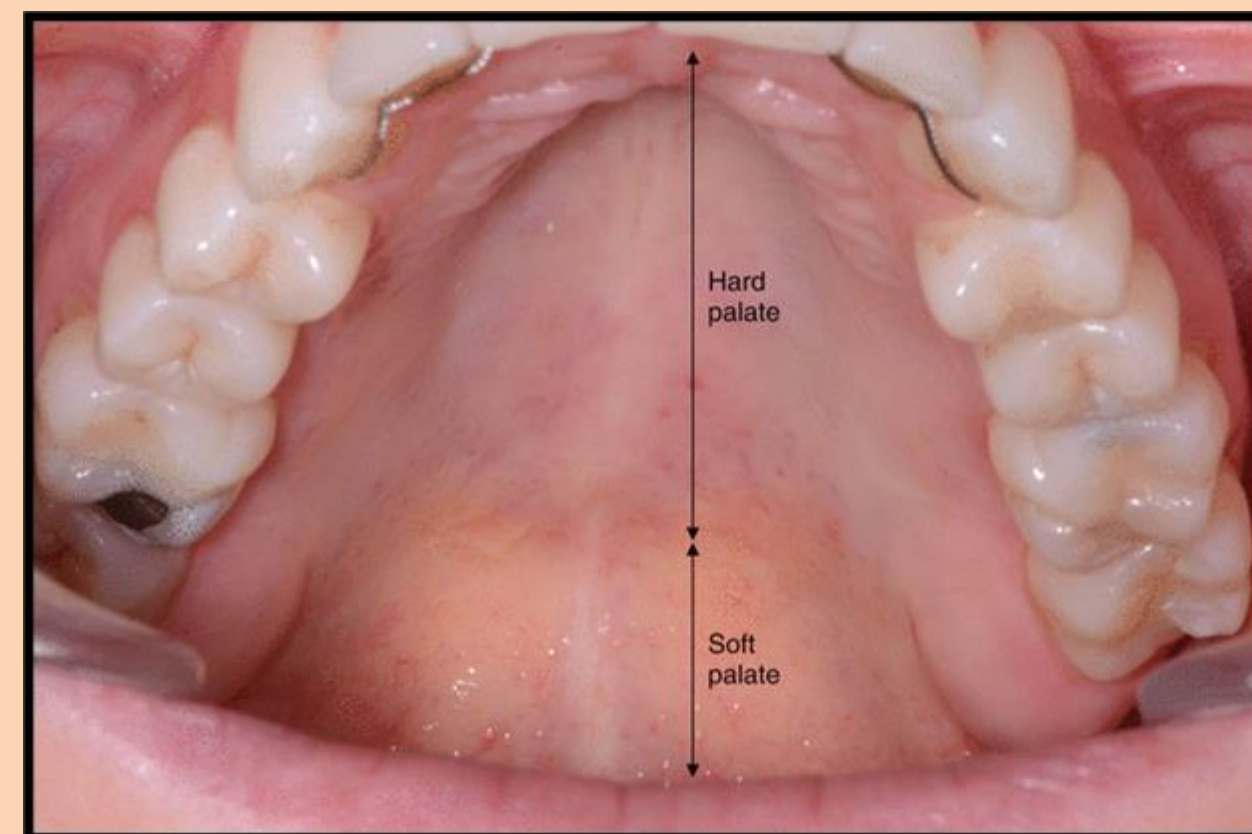
5. TONGUE

- **Where to look:**
 - Examine the **top** first by asking the patient to protrude the tongue forward, keeping the mouth open
 - To inspect the **lower** surface, the patient is instructed to touch the roof of the palate with the tip of his tongue
 - Check the **sides** of the tongue, movements of the tongue, and the floor of the mouth
- **What to look:** the appearance of ulcers, masses, red areas, or white areas can be early signs of cancer



6. HARD & SOFT PALATE

- **Hard palate (bony part)**- it is pink, firm and shows a corrugated pattern in the anterior portion
 - Check for changes in color, swelling, ulcer, and cleft
- **Soft palate (behind the hard palate)**- reddish-pink in color
 - Examine it for ulcers or swelling



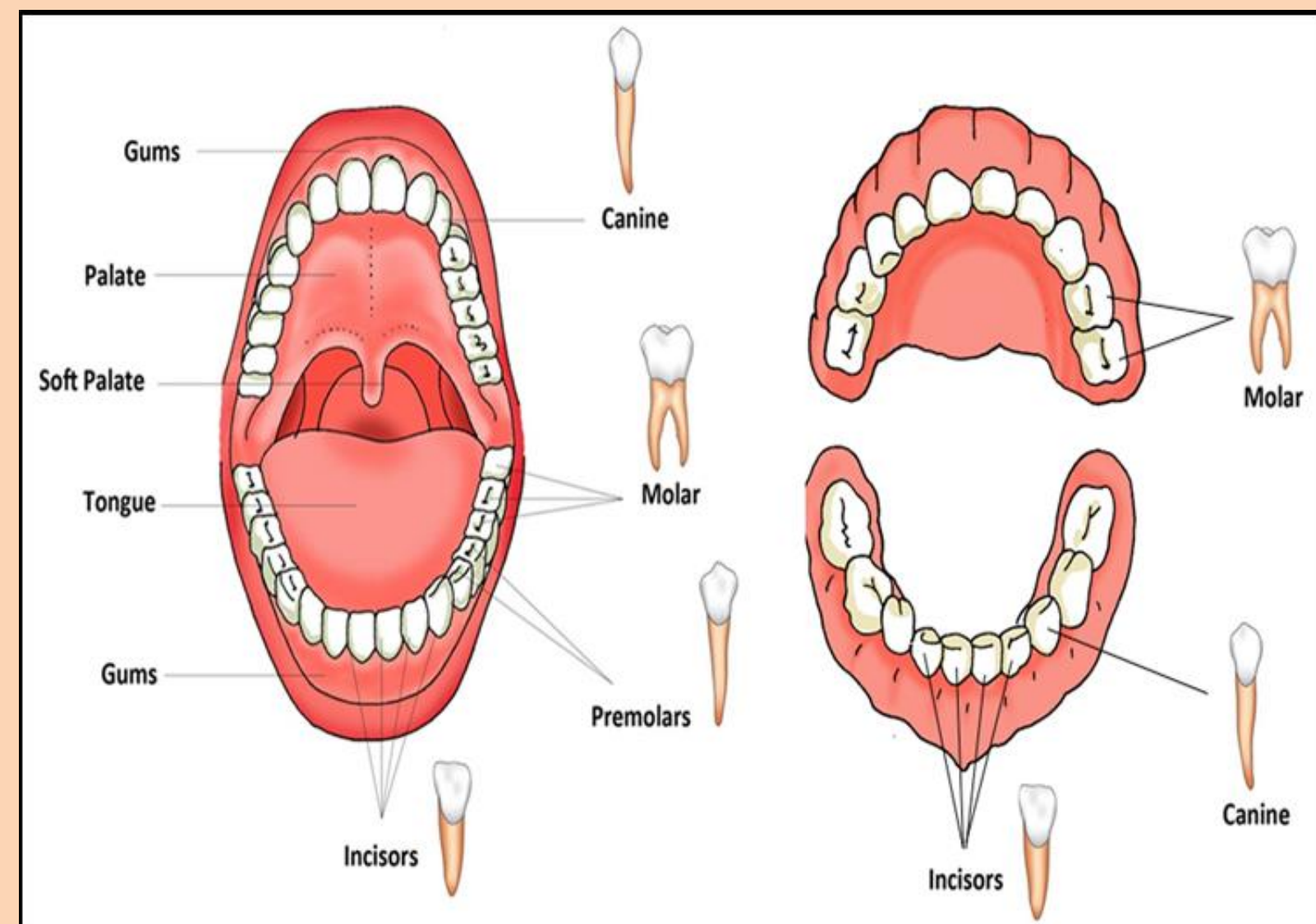
7. TEETH

Humans have 2 sets of teeth:

- Milk/baby/ primary teeth
- Permanent/ adult teeth

Total of 32 permanent teeth (In adults):

- 8 incisors,
- 4 canines,
- 8 premolars and
- 12 molars in both upper and lower arches.

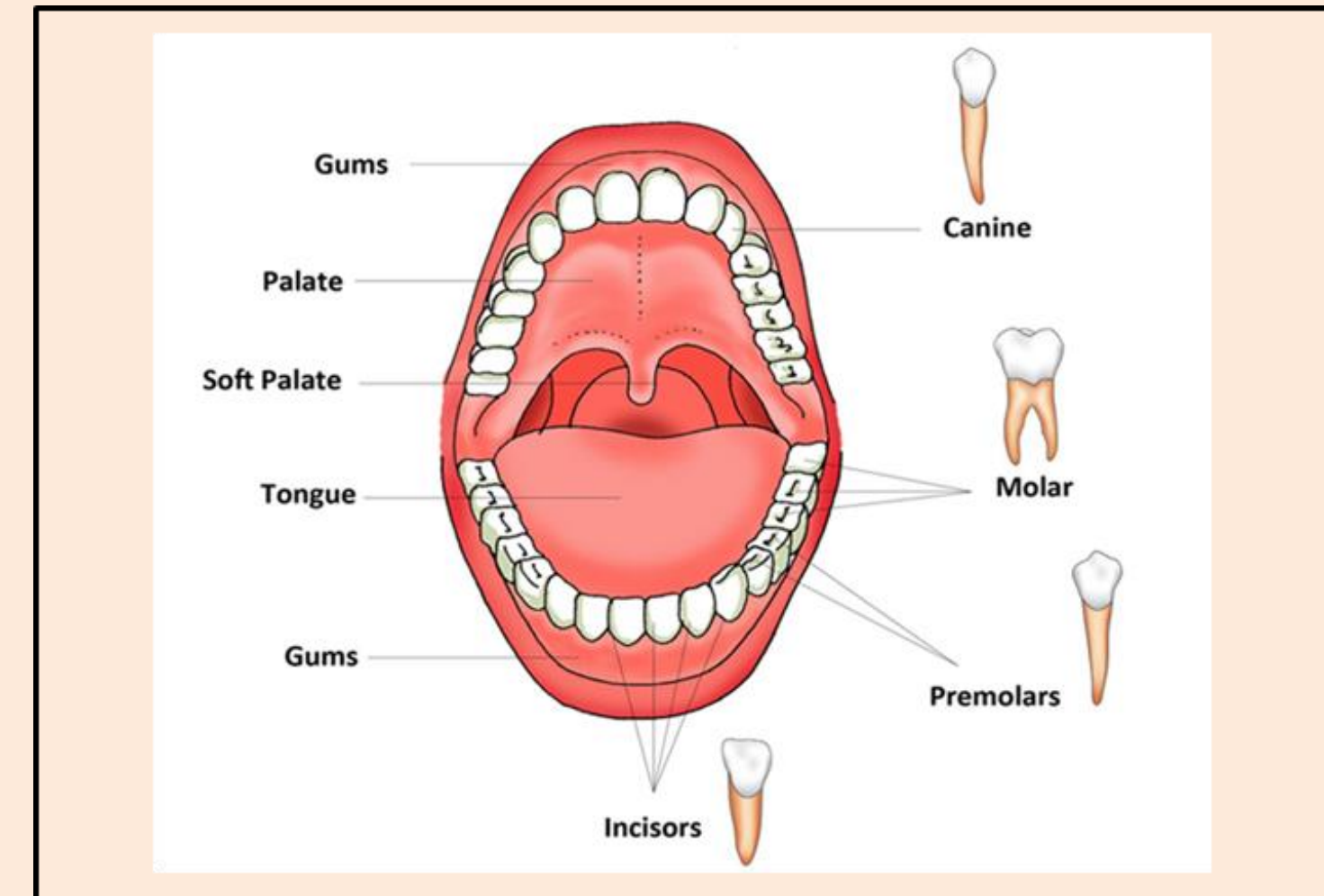




DIFFERENT TYPES OF TEETH

Incisors: They are front teeth, four in the upper arch and four in the lower arch. They are shaped to bite and cut food into small pieces.

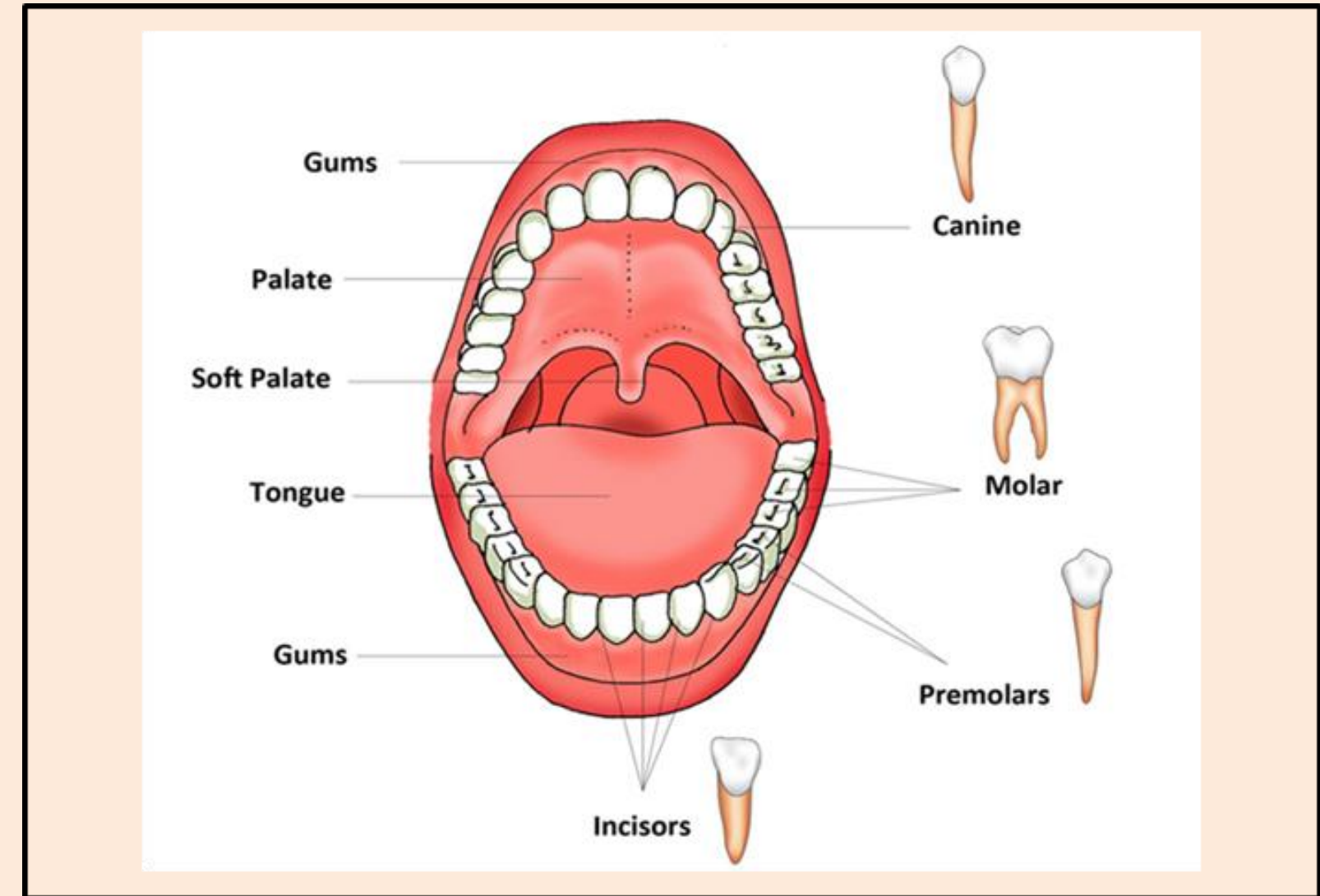
Canines: They are conical teeth at the corner of the mouth. Their function is to tear or shred food.

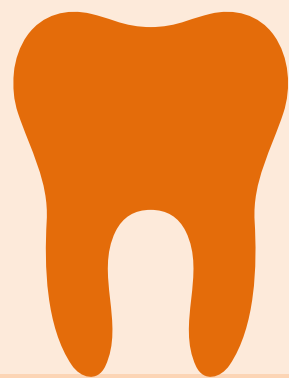


DIFFERENT TYPES OF TEETH

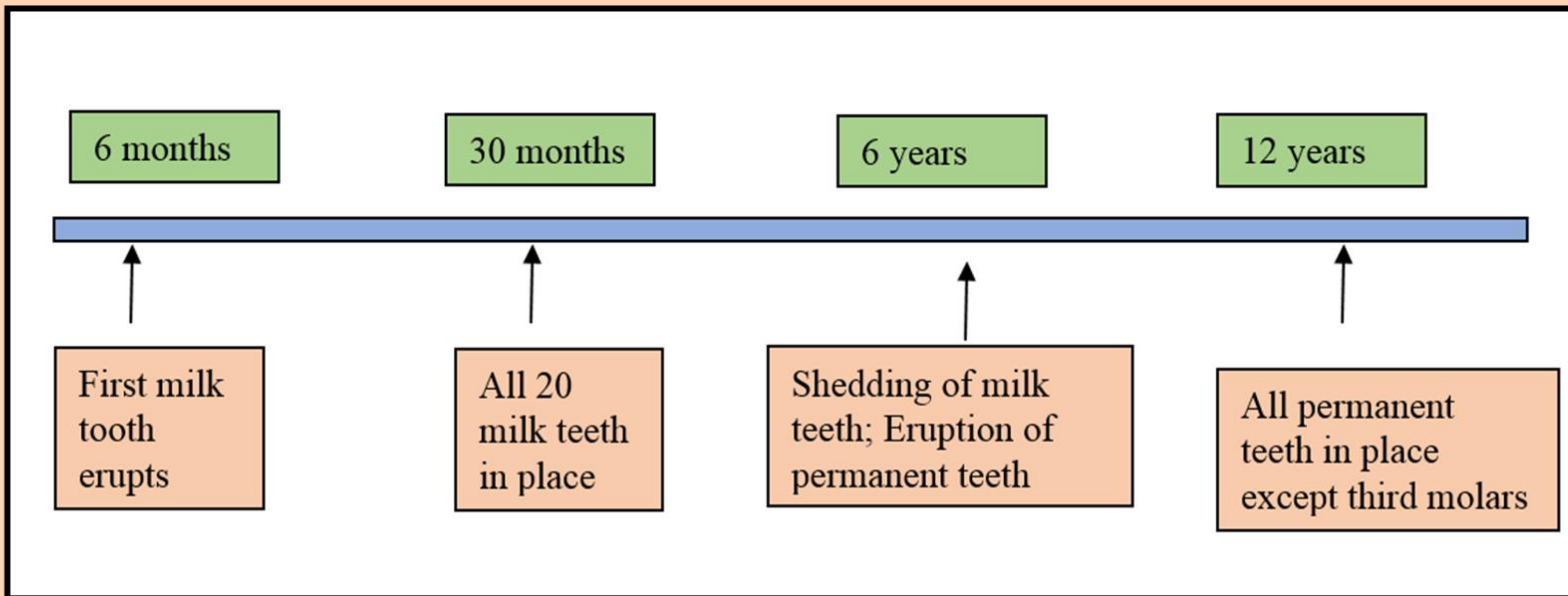
Premolars: These are two on each side of both the jaws just behind the canine. The functions of these teeth is to hold and crush food. Premolars are present only in adults.

Molars: They are three in number on each side of the jaws. They have bigger chewing surface for cutting food into smaller parts.





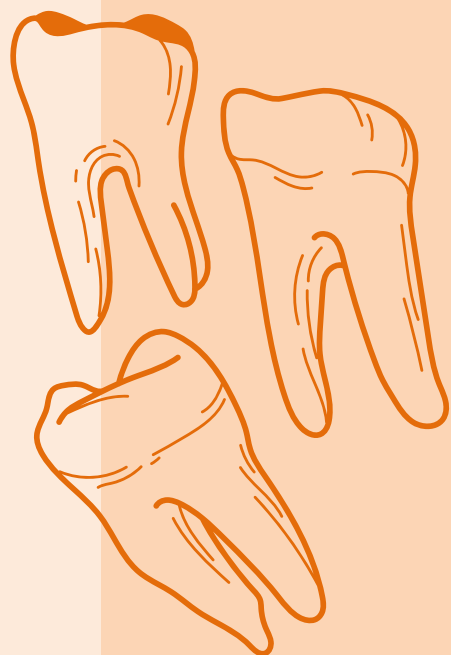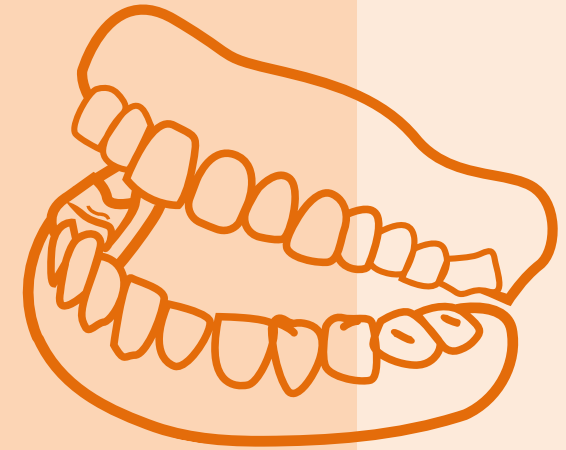ERUPTION OF TEETH TIMELINE



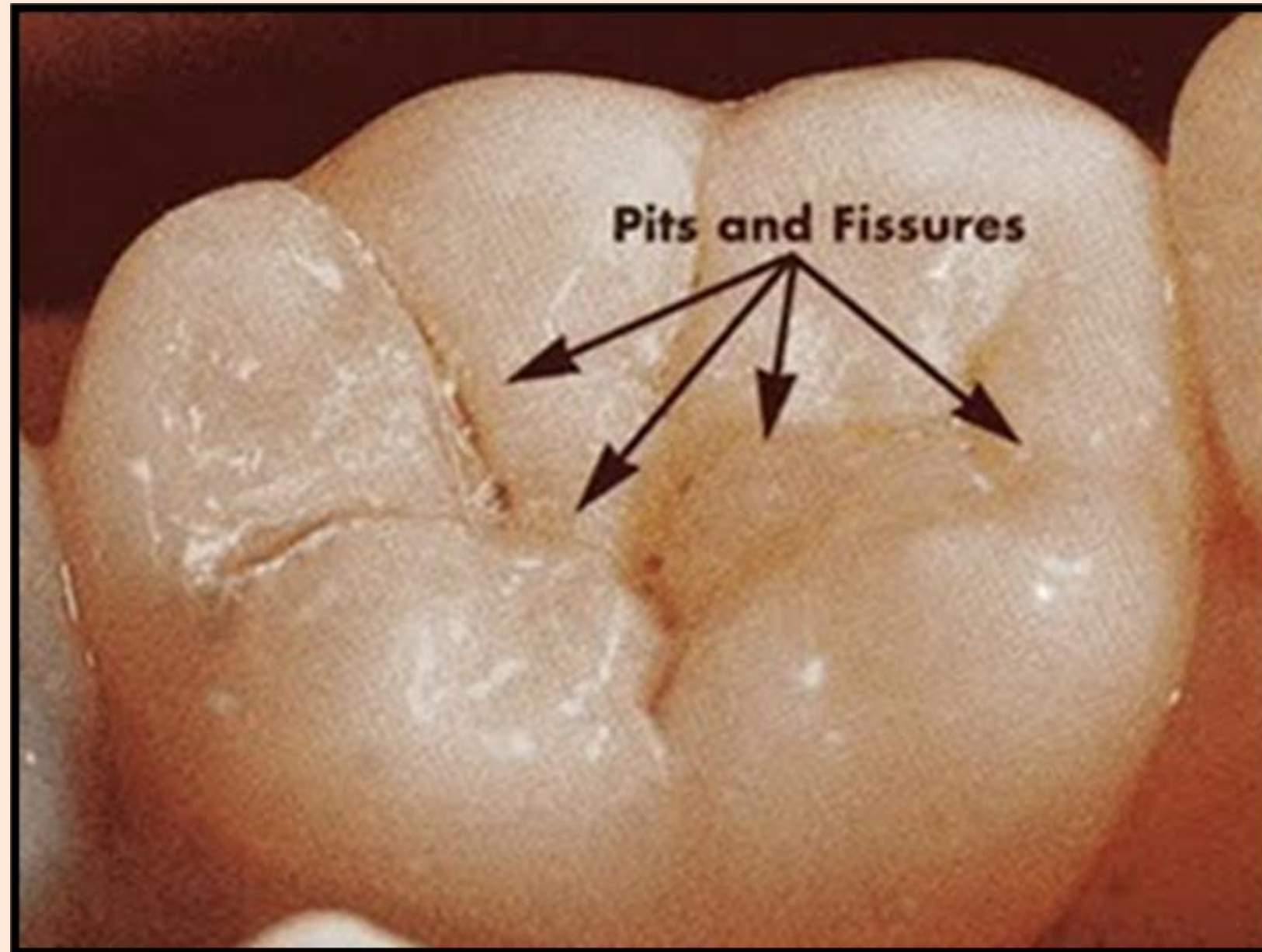


PARTS OF TEETH

- **Crown:** White visible part of the tooth.
- **Root:** Long portion inside the gums and bone.
- **Enamel:** The outermost hardest white cover
- **Dentin:** The inner less hard part and slight yellow in color
- **Pulp:** It surrounds the blood vessels and nerves of the tooth.



WHAT TO LOOK FOR?



Tooth decay

Missing Teeth



Small pits and fissures

Brown/black discoloration of teeth

Cavities on the tooth/between teeth

IMPORTANT POINTS TO KEEP IN MIND

- Wash your hands before starting oral examination
- Use disposable gloves
- Explain about the examination
- Instruments- sterilized after each time they are used





सत्यमेव जयते



Thank You

